

Trace Metal Effects on Gill Epithelium of Common Carp, *Cyprinus carpio* L. (Cyprinidae)

Elenka Georgieva¹, Iliana Velcheva², Vesela Yancheva², Stela Stoyanova²

¹ Department of Developmental Biology, Section of Histology and Embryology, Faculty of Biology, University of Plovdiv, Bulgaria

² Department of Ecology and Environmental Conservation, Faculty of Biology, University of Plovdiv, Bulgaria;
E-mail: anivel@abv.bg

Abstract: We investigated the histological alterations in gill epithelium of common carp (*Cyprinus carpio* L.) from Topolnitsa Reservoir in Bulgaria, which experiences various types of contaminant stress, mainly trace metal pollution from mining activities. Water, sediment and fish gill samples were collected for metal content analysis and the concentrations of As, Cd, Cu, Ni, Pb, and Zn were determined. Severe changes detected were hyperplasia at different levels of proliferation and lamellar fusion as well as degeneration of the gill epithelium. Those changes were linked to the metal concentrations due to anthropogenic contamination in the study area.

Key words: Gill epithelium, common carp, histology, trace metals, water, sediments

Introduction

Trace metals emanating either from natural sources or from anthropogenic activities interact with aquatic organisms as mixture of more than one metal or in combination with organic pollutants (PANDAY 2008). Fish have been found to be good indicators of trace metal contamination in aquatic systems (MOISEENKO *et al.* 2008). In addition, fish gills are the first organs that come in contact with environmental pollutants and are sensitive indicators for identifying the effects of water toxicants on fish organisms (HEIER *et al.* 2009). Histological changes in gills are recognised as a valid and fast method to determine the damage caused in fish by the exposure to different pollutants (ARELLANO *et al.* 1999). There are reports on various histological changes in gills, under the effects of metal pollution in water both in field and laboratory conditions, but it is often difficult to decide whether morphological alterations are adaptive or destructive (TKACHEVA *et al.* 2004).

Topolnitsa Reservoir was built on the Topolnitsa

River in Bulgaria. The reservoir has been intensively contaminated for many years and the main sources of pollution are the copper mines, metallurgy plants, non-ferrous smelters and mine tailings. There are no data on the trace metal levels in the water basin and their effects on fish published in the last 20 years. Common carp (*Cyprinus carpio* L.) is one of the species with economic importance, which has a wide geographic distribution in Bulgaria and it is abundant in Topolnitsa Reservoir as well. Furthermore, carps were proposed as test organisms in toxicological assays because they can survive and accumulate contaminants even at heavily polluted sites (REYNDERS *et al.* 2008).

The first objective of this study is to determine the degree of contamination by analysing samples of both abiotic (water, sediments) and biotic (fish) components. The second objective is to study the histological alterations of gill epithelium of common carp from Topolnitsa Reservoir in Bulgaria.

Material and Methods

The study was conducted in Topolnitsa Reservoir (42° 25' 90" N 23° 59' 38" E) close to the village of Muhovo, South-West Bulgaria, in spring 2012. All analyses were carried out at the Regional Laboratory of the Executive Environment Agency in Plovdiv, Bulgaria. The chemicals used in this study were purchased from Sigma Chemical Co. and were of analytical grade.

The water samples for trace element analysis were collected (ISO 5667-4:2002) near the dam at three stations. Prewashed double capped polyethylene bottles were used. They were rinsed three times with the water to be sampled prior to sampling. The samples were acidified with 1% HNO₃ and stored on ice for as short time as possible in order to minimise the changes in metal physicochemical characteristics before analysis. During the field trip, pH, temperature (°C), and conductivity (µS/cm) were recorded simultaneously, using a pH-meter (Multi 340i, WTW). Trace metal content in water was analysed by using ISP-MS (Agilent 7500ce, Japan) and reported as mg/L. Certified reference standard for trace metals in waters SRM 1643e (National Institute of Standards and Technology, USA) was used. All results showed a good agreement with the standards. The recovery values for the water samples were between 96% and 105%. The trace metal concentrations in the present study were compared with the maximum permissible metal concentrations in waters according to the Bulgarian legislation (REGULATION NORM OF THE PRIORITY SUBSTANCES IN SURFACE WATERS 2010; REGULATION NORM – H 4 OF THE QUALITY AND CHARACTERIZATION OF SURFACE WATERS 2012) and also according to some international norms (DIRECTIVE 83/513/EU, WHO/UNEP 1989).

The sediments were collected simultaneously with the water samples near the dam with small stainless steel blades and kept in clean polyethylene zip-lock bags on ice. They were later sieved through a series of plastic sieves (VEB Metallweberei, Neustadt/Orla, Germany) in order to remove different fragments and left to air-dry. Sediments were digested in a microwave system (Milestone ETHOS PLUS, Italy) and the trace metal content was analysed by using ISP-MS (Agilent 7500ce, Japan) according to ISO 17294-2:2005, and reported as mg/kg (n=3). Certified reference standards for trace metals in sediments CNS 301-04-050 and CNS 015-050 (Resource Technology Corporation, USA and UK) were used. All results showed a good agreement with the standards and the recovery values were between 92% and 101%.

Common carp (97.7±13 g, 15.3±0.5 cm) was caught by using fishing nets and a boat. All fish samples were collected by the international standard procedures for determination of metal accumulation given in the EMERGE Protocol (ROSSELAND *et al.* 2003). The gill samples were kept on ice in the field and then deep-frozen (-20°C) until the analysis began. The gills were digested according to the method described by KINGSTON, JASSIE (1988), using a microwave digestion system (Milestone ETHOS PLUS, Italy). The metal content in the gills was analysed by using ISP-MS (Agilent 7500ce, Japan) and reported as µg/kg wet weight (n=10). Certified reference standard DORM-3 (National Research Council Canada, Ottawa, Ontario, Canada) was used. All results showed a good agreement with the standards and recovery values were between 91% and 100%. All experiments were conducted in accordance with national and international guidelines of the European Parliament and the Council on the protection of animals used for scientific purpose (DIRECTIVE 2010/63/EU).

All gill samples were placed in vials with 10% neutrally buffered formaldehyde solution (pH = 7) for 12 h. They were rinsed in tap water, dehydrated in a graded series of ethanol concentrations, cleared in xylene, embedded in paraffin wax with melting point of 54-56°C, sectioned to a thickness of 5-7 µm, using a rotary microtome (model 840, American Optical Corp.) and mounted on sterilised glass slides. The sections were then deparaffinised, stained with hematoxylin and eosin (H&E) for histological examinations and prepared for light microscopy analysis (WOODS, ELIS 1994). Histological changes in gill epithelium were observed and photographed by using microscope model SE (Nikon, Japan), equipped with a digital camera DCE-2 and AMCAP software version 1.0.2. Healthy common carps (92±23.2 g, 13.9±3.9 cm) were obtained from the fish-breeding farm „Eco Fish“ located in the village of Trivoditsi, near Plovdiv, Bulgaria. They were used as reference fish in order to compare the fish morphological structure of the investigated species.

Histological alterations in gill epithelium were assessed semi-quantitatively by using the grading system of PEEBUA *et al.* (2006), which we slightly modified. Evaluation of the histological changes was carried out and presented as an average value in percentages. Each grade represents specific histological characteristics and it is categorised by the alterations in the architecture of the gill surface as follows: no histological alterations – (-); mild histological alterations – 10-20% - (+/-); moderate histological alterations – 30-50% - (+); severe histological alterations

– 60-80% - (++) and very severe histological alterations – above 80% (+++) (Table 1).

The raw data about trace elements concentrations in water, sediments and fish gills were processed using descriptive statistics. Software package STATISTICA 7.0 (StatSoft Inc. 2004) was used as it allows mathematical assessment with low number of samples ($n > 2$). The trace metal data was subjected to correlation analysis and principle component analysis (SPSS 17.0, IBM Corp. 2008). Statistical significance was accepted at $P < 0.05$.

Results

The general water chemistry data were as follows: pH = 9.4 ± 0.02 , temperature ($^{\circ}\text{C}$) = 21.5 ± 0.1 , conductivity (mS/cm) = 0.32 ± 0.005 , dissolved oxygen (mg/L) = 11.2 ± 0.2 , and oxygen saturation (%) = 133. The concentrations of trace metals in the water are listed in Table 1.

The concentrations of trace metals in the sediments are also listed in Table 1. No maximum permissible levels of trace metals in sediments have been established yet in Bulgaria.

Table 1. Trace metal concentrations in sediments ($n=3$), water ($n=3$) and fish gills ($n=10$) in Topolnitsa Reservoir (average \pm standard deviation). *Less than the detection limit

Trace element	Sediment (mg/kg)	Water (mg/l)	Fish gill (mg/kg wet weight)
As	26.67 \pm 23.58	0.0165 \pm 0.0081	0.0765 \pm 0.02
Cd	1.07 \pm 0.98	0.0004 \pm 0.0002	0.0695 \pm 0.001
Cu	71 \pm 20.39	0.017 \pm 0.002	4.010 \pm 1.64
Ni	44 \pm 25.14	0.0027 \pm 0.0001	0.207 \pm 0.19
Pb	18.33 \pm 11.81	<0.001*	0.224 \pm 0.21
Zn	123.66 \pm 84.63	0.006 \pm 0.003	63.345 \pm 1.21



Fig. 1. Representative light microphotographs of common carp gills (*Cyprinus carpio* L.) from Topolnitsa Reservoir (b, c). Intense lamellar epithelium lifting (thin arrows); epithelium interstitial oedema (thick arrows); stained with H&E (Magn. x 100, 200, 200)

The concentrations of trace metals in fish gills are also given in Table 1. Since average values for the trace metal concentrations were presented, the bio-concentration factor was not determined. However, it is clear that the metal concentrations were many times higher in the gills than in the water.

The reference fish gills we investigated presented normal distribution of cellular constituents and organisation pattern of primary and secondary lamellae, and blood vessels. The gill epithelium histology of the reference specimens appeared typical for teleost fish. With regard to the grading system we proposed, the control common carp histological characteristics were evaluated as relatively normal (-) (Fig. 1a). However, different histological alterations were detected in the gill epithelium of common carp from Topolnitsa Reservoir. Lamellar epithelium lifting was determined in more than 80% of the lamellae surface in the gill arches of all investigated fish. (Table 2, Fig. 1b, c). We observed oedema which emerged at the base of secondary lamellae in the filamentous epithelium area (Table 2). In addition, we verified proliferation of filamentous stratified epithelium, which was increased in thickness (Table 2). This proliferation varied in the degree to which it occurred (Fig. 2a, b). We observed fusion which is known to be the most serious form of proliferation in all ten common carps investigated. (Table 2, Fig. 2c). The histological structure of the gill filaments in particular areas was severely altered and the lamellae were completely destroyed. Instead of them, the epithelium formed a thick layer consisting of large number of cells and surface invaginations

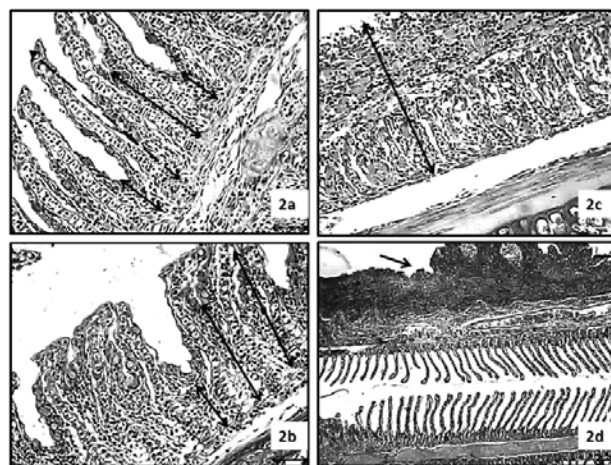


Fig. 2. Representative light microphotographs of common carp gills (*Cyprinus carpio* L.) from Topolnitsa Reservoir. Gill epithelium proliferation along lamellae axis (a, b, c, d); various degree of proliferation (a, b); fusion in gill epithelium (c), permanent proliferation (arrow) which causes multilayer cell accumulation (d); stained with H&E (Magn. x 200, 200, 200, 100)

Table 2. Semiquantitative scoring of gill epithelium of common carp (*Cyprinus carpio*) collected in Topolnitsa Reservoir, Bulgaria. (-) – no histological alterations, representing normal histological structure; (+/-) – mild histopathological alterations – 10-20%; (+) – moderate histopathological alterations – 30-50%; (++) – severe histopathological alterations – 60-80%; (+++) – very severe histopathological alterations – above 80%

Histological alterations in gill epithelium	I	II	III	IV	V	VI	VII	VIII	IX	X
Lifting of the lamellar epithelium	+++	+++	+++	+++	+++	+++	+++	+++	+++	+++
Oedema in the filamentar epithelium	+	+/-	+/-	+/-	-	+/-	+/-	+/-	+	-
Proliferation of filamentar epithelium	++	++	++	++	++	++	++	++	++	++
Lamellar fusion	++	+	+/-	++	+/-	+	+	++	++	++
Gill epithelium degeneration	-	-	+/-	-	+/-	+/-	-	+/-	-	-

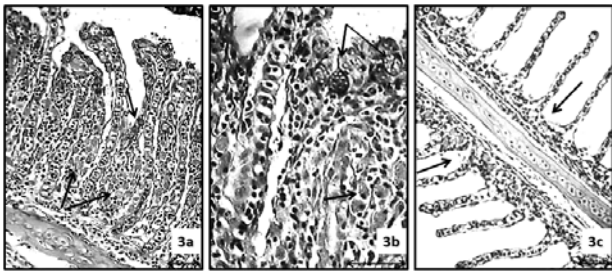


Fig. 3. Representative light microphotographs of common carp gills (*Cyprinus carpio* L.) from Topolnitsa Reservoir. Increase in the number of mucous cells in areas with severe gill epithelium proliferation (a, b); gill epithelium degeneration (c); stained with H&E (Magn. x 200, 400, 200)

(Fig. 2d). An increase in the number of mucous cells in the areas with severe gill epithelium proliferation was also recorded (Fig. 3b). Furthermore, gill epithelium degeneration was found. It was represented by a reduction in the stratified filamentous epithelium, which we assumed as a direct result of cell death (Table 2, Fig. 3c).

Discussion

In general, the literature on the water quality of Topolnitsa Reservoir is quite old or scarce. In the water samples collected near the dam KOLCHAKOV *et al.* (1994) measured levels of toxic metals 2 to 5 times higher than the maximum levels set by law. The metal concentrations that we determined were lower than the proposed maximum permissible levels set in the Bulgarian legislation and also according to some international norms (DIRECTIVE 83/513/EU, WHO/UNEP 1989). However, all investigated met-

als seem to be present constantly in the Topolnitsa Reservoir surface waters.

Sediments represent an important sink for trace metals in aquatic systems, and metal concentrations in sediments can be several orders of magnitude greater than in the overlying water. Sediment-associated metals pose a direct risk to detrital and deposit-feeding benthic organisms, and may also represent a long-term source of contamination to higher trophic levels (EIMERS *et al.* 2001). The statistical analysis did not show a significant correlation between the metals in the two components, while the higher trace metal concentrations in sediments gave solid proof of the metal accumulation process. Therefore, the contamination of the reservoir seems to be a complex process and it is due not only to the continuous source of industrial wastewater metals, but also due to the release of toxicants accumulated in the past. Based on these results, we assume that the chronic trace metal presence in the water basin has impacted the biota seriously.

This study examined the levels of trace metals that derived from natural sources (*i.e.* sediment-water interactions), as well as from ongoing anthropogenic activity. Accumulation process of the investigated toxicants was assessed by measuring their levels in water, sediment samples, and fish gills, respectively. Statistical tests did not show a significant correlation between the trace metal concentrations in the water and these in gills. However, the metal levels in gills were higher and thus, we consider that the gill function is negatively influenced. In addition, the principle component analysis showed that the sediment as a factor has a stronger influence on the toxicant levels in the gills than the water.

Finally, we observed severe histological alterations in the gill epithelium of fish collected in the field, which are also mentioned elsewhere. However, it should be noted that most of the authors performed their experiments under laboratory conditions (CAMARGO, MARTINEZ 2007, LIU *et al.* 2010, VELCHEVA *et al.* 2010a, b, SANTOS *et al.* 2011). Like THOPHON *et al.* (2003) we consider that the presence of oedema, along with the lifting of the epithelium, found in our study as well, was the first sign of pathology in fish and one of the more frequent lesions observed in gill epithelium of fish exposed to trace metals. Hyperplasia in gill epithelium of freshwater fish species induced by trace metals was reported by FIGUEIREDO-FERNANDES *et al.* (2007). However, we report for the first time the different levels of gill epithelium proliferation and areas of severely damaged histological structure of gills. Similarly to FONTAINHAS-FERNANDES *et al.* (2007) and MOHAMED (2009), we also observed hyperactivity of the mucous cells. We think that the increase in the number of these cells would cause an intense mucous secretion and thicken the mucous layer. In addition, we assume that the emergence of fusion and additional significant thickening of the filamentous epithelium, which we observed, could have impact on the respiration and osmoregulation processes. Thus, the investigated fish might experience oxygen stress and the trace metal ions could affect the cell metabolism. Degenerative changes in fish gill epithelium were reported in the work of HASSAN (2011). In our study we consider that the hyperplastic alterations in the gill epithelium were predominant because the adaptive and protective mechanisms had worked towards forcing a cell division instead of cell death.

Conclusions

This study combines the determination of contamination levels in three components (sediments, water

and biota) of the freshwater ecosystem of Topolnitsa Reservoir. In conclusion, the study shows the complex mechanisms of six trace metals and their impact on the function and structure of the carp gills. Even though some of the trace metal concentrations were below the detection limit of the instrument, while others did not exceed the maximum acceptable norms set by law, arsenic, cadmium, copper, nickel, lead, and zinc seem to be consistently present in the surface waters of Topolnitsa Reservoir. Therefore, we consider that the toxic effects on fish are chronic due to much higher trace metal concentrations in the sediments. In addition, we link the metal concentrations that we determined to the severe histological alterations in common carp gill epithelium, observed by us. On the one hand, the histological alterations prove that serious negative disturbances to the cell metabolism are ongoing. On the other hand, these alterations could also allow fish to activate their defensive and adaptive mechanisms, which might help them to survive in contaminated environment. Moreover, the adaptive mechanisms are associated with building some protective barriers in fish gills, which would hamper the transport of waterborne toxicants into the organism. These changes can be used as a successful biomarker in field assessment and monitoring programs on freshwater ecosystems contaminated with trace metals. We, therefore, suggest that further investigations in this particular field should be carried out to better understand the deleterious effects of trace metals and protective mechanisms in fish.

Acknowledgments: This study was funded by the Department of Scientific Research (NPD), contract BF 006. The authors express sincere gratitude to the East Aegean Sea River Directorate, Plovdiv and Ministry of Environment and Water of Bulgaria. We would like to thank the Basin Directorate for Water Management – East Aegean Region for helping in water sampling and heavy metal content analysis.

References

- ARELLANO J.M., V. STORCH, C. SARASQUETE 1999. Histological changes and copper accumulation in liver and gills of the Senegales sole, *Solea senegalensis*. – *Ecotoxicology and Environmental Safety*, **44**: 62-72.
- CAMARGO M.M.P, C.B.R. MARTINEZ 2007. Histopathology of gills, kidney and liver of a Neotropical fish caged in an urban stream. – *Neotropical Ichthyology*, **5**: 327–336.
- DIRECTIVE 2010/63/EU of the European Parliament and of the Council on the protection of animals used for scientific purposes. – Official Journal of the European Union.
- DIRECTIVE 1983/513/EU of the European Parliament and of the Council on limit values and quality objectives for cadmium discharges. – Official Journal of the European Union.
- EIMERS R.D., R.D. EVANS, P.M. WELBOURN 2001. Cadmium accumulation in the freshwater isopod *Asellus racovitzai*: the relative importance of solute and particulate sources at trace concentrations. – *Environmental Pollution*, **111**: 247–253.
- FIGUEIREDO-FERNANDES A., J.V. FERREIRA-CARDOSO, S. GARCIA-SANTOS, S.M. MONTEIRO, J. CARROLA, P. MATOS, A. FONTAINHAS-FERNANDES 2007. Histopathological changes in liver and gill epithelium of Nile tilapia, *Oreochromis niloticus*, exposed

- to waterborne copper. – *Pesquisa Veterinária Brasileira*, **27**: 103-109.
- FONTAÍNHAS-FERNANDES A., A. LUZIO, S.G SANTOS., J. CARROLA, S. MONTEIRO 2008. Gill histopathological alterations in Nile tilapia, *Oreochromis niloticus* exposed to treated sewage water. – *Brazilian Archives of Biology and Technology*, **51** (5): 1057-1063.
- HASSAN B. 2011. The effect of copper and cadmium on oxygen consumption of the juvenile common carp, *Cyprinus carpio* (L.). – *Mesopotamian Journal of Marine Science*, **26** (1): 25-34.
- HEIER L.S., I.B. LIEN, A.E. STRØMSENG, M. LJØNES, B.O. ROSSELAND, K.E. TOLLEFSEN, B. SALBU 2009. Speciation of lead, copper, zinc and antimony in water draining a shooting range - time dependant metal accumulation and biomarker responses in brown trout (*Salmo trutta* L.). – *Science of the Total Environment*, **407**: 4047-4055.
- ISO 17294-2:2005. Water quality. Application of inductively coupled plasma mass spectrometry (ICP-MS) - Part 2: Determination of 62 elements.
- ISO 5667-4:2002. Water quality. Water sampling – Part 4: Sampling Guidance on sampling from lakes, natural and man-made.
- KINGSTON H.M., L.B. JASSIE 1998. Safety Guidelines for Microwave Systems in the Analytical Laboratory – In: KINGSTON H.M., L.B. JASSIE (eds.): Introduction to Microwave Acid Decomposition: Theory and Practice. ACS Professional Reference Book Series, American Chemical Society, Washington, DC. 33 p.
- KOLCHAKOV I., A. STANCHEV, A. BRASHNAROVA, A. STANISLAVOVA 1994. A research on contamination with arsenic and copper on soils and plants from the field of Pazardjik using water from Topolnitsa Dam. – *Soil Science, Agrochemistry and Ecology*, **29**: 4-6 (in Bulgarian).
- LIU X. J., Z. LUO, B.X. XIONG, X. LIU, Y.H. ZHAO, G.F. HU, G.J. LV 2010. Effect of waterborne copper exposure on growth, hepatic enzymatic activities and histology in *Synechogobius hasta*. – *Ecotoxicology and Environmental Safety*, **73**: 1286–1291.
- MOHAMED F.A.S. 2009. Histopathological Studies on *Tilapia zillii* and *Solea vulgaris* from Lake Qarun, Egypt. – *World Journal of Fish and Marine Science*: **1** (1), 29-39.
- MOISEENKO T.I., GASHKINA N.A., SHAROVA YU.N., KUDRYAVTSEVA L.P 2008. Ecotoxicological assessment of water quality and ecosystem health: A case study of the Volga River. – *Ecotoxicology and Environmental Safety*, **71**: 837-850.
- PANDEY S., S. PARVEZ, R. AHAMD ANSARI, M. ALI, M. KAUR, F. HAYAT, F. AHMA, SH. RAISUDDIN 2008. Effects of exposure to multiple trace metals on biochemical, histological and ultrastructural features of gills of a freshwater fish, *Channa punctata* Bloch. – *Chemico-Biological Interactions*, **174** (3): 183–192.
- PEEBUA P, KRUATRACHUEA M., POKETHITHYOOKA P., P. KOSIYACHINDAA 2006. Histological Effects of Contaminated Sediments in Mae Klong River Tributaries, Thailand, on Nile tilapia, *Oreochromis niloticus*. – *Science Asia*, **32**: 143-50.
- REGULATION NORM OF THE PRIORITY SUBSTANCES IN SURFACE WATERS, 2010 (in Bulgarian).
- REGULATION NORM – H 4 OF THE QUALITY AND CHARACTERIZATION OF SURFACE WATERS, 2012 (in Bulgarian).
- REYNDERS H., L. BERVOETS, M. GELDERS, W.M DE COEN, R. BLUST 2008. Accumulation and effects of metals in caged carp and resident roach along a metal pollution gradient in Flanders, Belgium. – *Science of the Total Environment*, **391**: 82–95.
- ROSSELAND B.O., J.C. MASSABUAU, J. GRIMALT, R. HOFER, R. LACKNER, G. RADDUM, S. ROGNERUD, I. VIVES 2003 Fish Ecotoxicology: European Mountain Lake Ecosystems Regionalisation, Diagnostic and Socio-economic Evaluation (EMERGE). Fish Sampling Manual for Live Fish, Norwegian Institute for Water Research (NIVA), Oslo, Norway., 7pp.
- SANTOS D.C.M, S.L.P. MATTA, J.A. OLIVEIRA, J.A.D. SANTOS 2011. Histological alterations in gills of *Astyanax aff. bimaculatus* caused by acute exposition to zinc. – *Experimental and Toxicologic Pathology*, **64** (7-8): 861-866.
- THOPHON S., M. KRUATRACHUE, E.S UPATHAM, P. POKETHITHYOOK, S. SAHAPHONG, S. JARITKHUAN 2003. Histopathological alterations of white seabass, *Lates calcarifer*, in acute and subchronic cadmium exposure. – *Environmental Pollution*, **121**: 307-320.
- TKACHEVA V., H. HYVÄRINEN, J. KUKKONEN, L.P. RYZHKOV, I.J. HOLOPAINEN 2004. Toxic effects of mining effluents on fish gills in a subarctic lake system in NW Russia. – *Ecotoxicology and Environmental Safety*, **57**: 278–289.
- US ENVIRONMENTAL PROTECTION AGENCY 2002. National recommended water quality criteria: 2002-correction: EPA-822-R-02-047, Washington DC, USA.
- VELCHEVA I., A. ARNAUDOV, E. GEORGIEVA 2010a. Influence of Zinc on gill morphology of Gibelio carp (*Carassius gibelio*). – *Ecologia Balkanica*, **2**: 19-23.
- VELCHEVA I., E. TOMOVA, D. ARNAUDOVA, A. ARNAUDOV 2010b. Morphological study on gills and liver from freshwater species from “Studen kladenec” Dam Lake. – *Bulgarian Journal of Agricultural Sciences*, **16** (3): 364-368.
- WHO/UNEP (1989) GEMS - Global fresh water quality. Published on behalf of the World Health Organization/United Nations Environment Programme. Oxford, Blackwell Reference.
- WOODS E., R.C. ELLIS (Eds) 1994. Laboratory Histopathology: A Complete Reference. Chrichill Livingstone, New York, **1-2**.

Received: 11.03.2013
Accepted: 26.03.2014

Performance of common carp, *Cyprinus carpio* L. and Nile tilapia Historical information on common carp (*Cyprinus carpio*) in - NTNU.
Effects of Carp, *Cyprinus carpio* L., on Communities of Aquatic ...^Â Dactylogyrids (Dactylogyridae: Monogenea) on Common Carp (*Cyprinus carpio* L.) in Freshwaters of Iran and Description of the Pathogenicity of *D. sahuensis* B. Jalali^{1*} and M. Barzegar².
ABSTRACT Common carp is infected by five *Dactylogyrus* spp in both pond and natural lake habitats in Iran, namely *D. extensus* *D. anchoratus*, *D. achmerovi*, *D. vastator* and *D. sahuensis*.^Â Health Assessment of External Parasites of Cultured Cyprinidae in Pen Culture of Anzali Lagoon (In Persian). Pazoohesh Sazandegi, 47: 97-102. 3. Barzegar, M. and Jalali, B. 2002.